



Endoscopic Recognition and Management Strategies for Malignant Colorectal Polyps: Recommendations of the US Multi-Society Task Force on Colorectal Cancer

Aasma Shaikat,^{1,2} Tonya Kaltenbach,³ Jason A. Dominitz,^{4,5} Douglas J. Robertson,^{6,7} Joseph C. Anderson,^{6,7,8} Michael Cruise,⁹ Carol A. Burke,⁹ Samir Gupta,^{10,11} David Lieberman,^{12,13} Sapna Syngal,^{14,15,16} Douglas K. Rex¹⁷

This article is being published jointly in *Gastroenterology*, *The American Journal of Gastroenterology*, and *Gastrointestinal Endoscopy*.

Colorectal polyps are the precursors for most colorectal cancers (CRCs). Some colorectal polyps accumulate enough mutations to develop high-grade dysplasia and eventual invasion of dysplastic elements into the submucosa.¹ The invasion of dysplastic elements into the submucosa constitutes the clinical definition of CRC (Figure 1).

The term *malignant polyp* specifically refers to a colorectal lesion with cancer invading the submucosa but not extending into the muscularis propria. These lesions are classified as pT1 in the TNM classification system.² A synonymous and more modern term is *submucosally invasive lesion*. We will use the nomenclature of submucosal invasion throughout this document interchangeably when referring to a malignant polyp. The prevalence of cancer in colorectal polyps ranges from 0.2% to 5%.^{3–5}

Malignant polyps represent the earliest form of clinically relevant CRC in most patients because neoplastic invasion of the submucosa allows for possible lymphatic and vascular metastasis. The risk of metastasis depends on several endoscopic and histologic features. The clinical issue most often raised by malignant polyps is whether a patient with an endoscopically resected colorectal lesion with submucosal invasion requires surgical resection of the colorectal segment from which the lesion was removed. Some malignant polyps can be managed endoscopically because the risk of residual cancer in the bowel wall and/or adjacent lymph nodes is very low. Other endoscopically resected malignant polyps are best managed by surgical resection because endoscopic resection alone is accompanied by a very high risk of residual cancer and/or lymph node metasta-

ses. Optimal selection of patients with malignant polyps for endoscopic surveillance vs surgical treatment is important to minimize both the risk of residual cancer and the risk of surgery.^{6,7}

The purpose of this document is to guide endoscopists on how to assess lesions for endoscopic features associated with cancer, discuss how these factors guide endoscopic management, and to outline the factors that frame whether to advise surgery after a malignant polyp has been endoscopically resected.

The approach in the document is formulated around several specific key questions with relevant data from the literature that inform the recommendations. Specifically, we will discuss 6 key questions that address the following 3 tasks: endoscopic recognition of colorectal polyps with deep submucosal invasion that should be referred directly to surgery; optimal endoscopic resection techniques and specimen handling when an increased risk of superficial submucosally invasive polyp is identified; and weighing the risks and benefits of surgery when an endoscopically removed polyp is found to have submucosal invasion. Another document by the US Multi-Society Task Force (Kaltenbach, unpublished data) discusses optimal resection techniques for large and malignant polyps. This document excludes management of polyps associated with inflammatory bowel disease.

METHODS

Literature review

The English language medical literature was searched using MEDLINE, EMBASE, and Cochrane Database of Systematic reviews from January 1980 to December 31, 2018. A combination of key words and Medical Subject Headings were used and are summarized in Appendix 1. Review articles, meta-analyses, and editorials were reviewed for additional references.

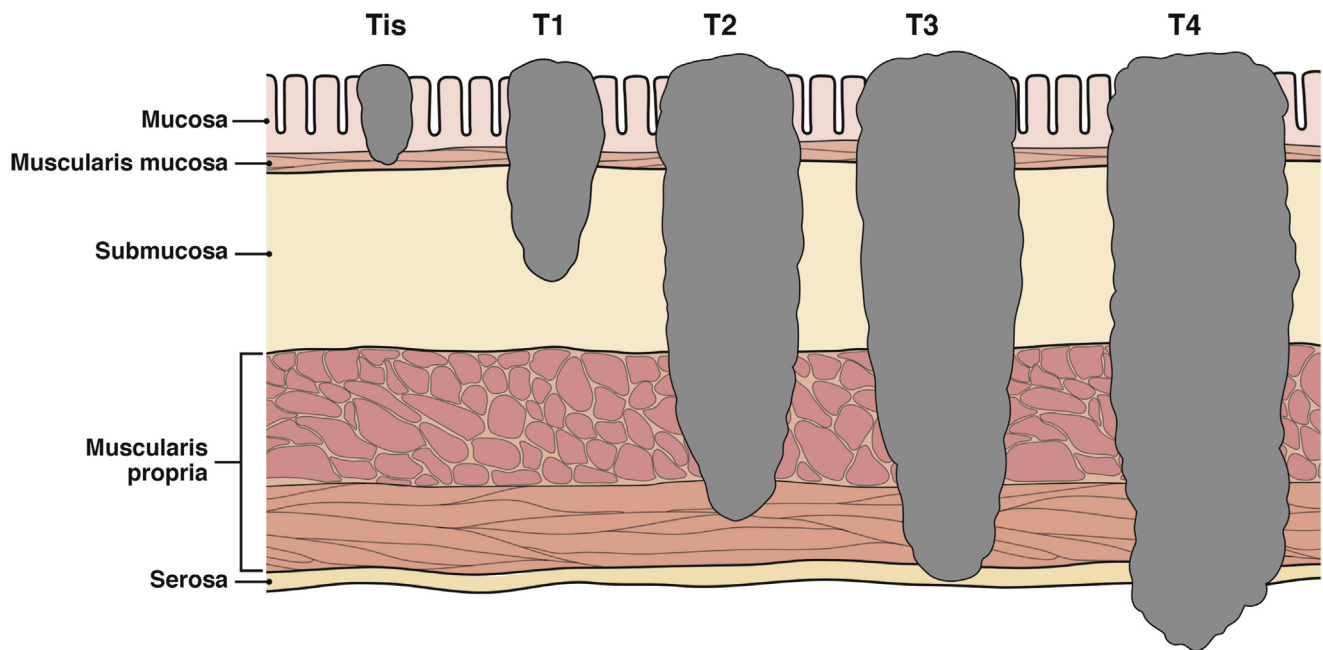


Figure 1. Cancer depth and AJCC classification.

Grading of evidence

The US Multi-Society Task Force on Colorectal Cancer (USMSTF) consists of gastroenterologists with expertise in colorectal neoplasia (ie, CRC and precursor lesions, such as polyps). The American College of Gastroenterology, the American Gastroenterological Association, and the American Society for Gastrointestinal Endoscopy are represented.

Summary tables and a draft document were circulated to members of the USMSTF and final guidelines were developed by consensus during several joint teleconferences. The document underwent committee review and governing board approval by all 3 societies. The USMSTF grades the quality of evidence and strength of recommendations using an adaptation of the Grading of Recommendations Assessment, Development and Evaluation (GRADE) approach.⁸ The GRADE process categorizes the quality of the evidence as high, moderate, low, or very low (Table 1). This categorization is based on an assessment of the study design (eg, randomized controlled trial or observational study), study limitations, inconsistency of results, indirectness of evidence, imprecision, and publication bias. The USMSTF members conduct literature searches to identify published articles that address the key issues discussed within these recommendations. These publications are supplemented both by review of citations from the identified articles, as well as other key references elicited from the subject matter experts on the Task Force. The GRADE process involves the collection of literature, analysis, summary, and a separate review of the quality of evidence and

strength of recommendations. The USMSTF members employed a modified, qualitative approach for this assessment based on exhaustive and critical review of evidence, without a traditional meta-analysis. The GRADE process separates evaluation of the quality of the evidence to support a recommendation from the strength of that recommendation. This is done in recognition of the fact that, although the quality of the evidence impacts the strength of the recommendation, other factors can influence a recommendation, such as side effects, patient preferences, values, and cost. Strong recommendations mean that most informed patients would choose the recommended management and that clinicians can structure their interactions with patients accordingly. Weak recommendations mean that patients' choices will vary per their values and preferences, and clinicians must ensure that patient care is in keeping with their values and preferences. Weaker recommendations are indicated by phrases such as "we suggest," and stronger recommendations are stated as "we recommend."

DEFINITIONS

Definition of malignant polyp

The term *malignant polyp* refers to a colorectal polyp including flat lesions with neoplastic invasion of the submucosa without extension into the muscularis propria.^{2,9} Another term for such lesions is *submucosally invasive polyps*. The Vienna classification system is a consensus between Western and Japanese pathologists for

TABLE 1. Grading of Recommendations Assessment, Development and Evaluation Ratings of Evidence

Rating of evidence	Definition
A: High quality	Further research is very unlikely to change our confidence in the estimate of effect
B: Moderate quality	Further research is likely to have an important impact on our confidence in the estimate of effect and may change the estimate
C: Low quality	Further research is very likely to have an important impact on our confidence in the estimate of effect and is likely to change the estimate
D: Very low quality	Any estimate of effect is very uncertain

classifying gastrointestinal epithelial neoplasia into 5 categories (Table 2).¹⁰ According to this classification, malignant polyps would fall under category 5.2 (submucosal carcinoma and beyond).

Malignant colorectal polyps are classified as pT1 in the 8th edition of the American Joint Committee on Cancer (AJCC) staging system (Figure 1).² This clinical definition of CRC excludes lesions with high-grade dysplasia, in which dysplastic changes are solely confined to the epithelium, lamina propria, or muscularis mucosa. Such lesions are classified as “Tis” in the AJCC staging system and National Comprehensive Cancer Network guidelines.^{2,9} Pathologists sometimes use the term *cancer* or *carcinoma in situ* or *intramucosal carcinoma* to describe such lesions. However, the use of terms such as *carcinoma* or *cancer* in describing lesions confined to the mucosa may cause undue alarm to endoscopists, surgeons, patients, or primary care providers, and can lead to unnecessary surgery. Although lesions confined to the mucosa, lamina propria, and the muscularis mucosa, are precancerous, they should not be confused with invasive colon cancer. The recommended management of adenomas with high-grade dysplasia should be endoscopic resection alone, because these lesions have no risk of residual neoplasia in the bowel wall or lymph nodes after complete endoscopic resection. We encourage endoscopists to discuss appropriate terminology with their pathologists and for pathologists to avoid the terms *carcinoma* and *cancer* in describing lesions confined to the mucosa, in order to reduce errors in understanding and clinical management.

ENDOSCOPIC AND HISTOLOGIC CLASSIFICATION SYSTEMS USED IN THIS DOCUMENT

The optimal management of malignant polyps in modern colonoscopy is based on the endoscopic diagnosis. Before endoscopic resection, every colorectal lesion detected at colonoscopy should undergo complete assessment of the lesion morphology, surface, and vessel pattern. A skilled assessment, often accompanied by dye-based chromoendoscopy or electronic-based image enhancement, will identify lesions with endoscopic features that are specific for deep submucosal invasion of can-

TABLE 2. Vienna Classification of Gastrointestinal Epithelial Neoplasia

Category	Description
1	Negative for neoplasia/dysplasia
2	Indefinite for neoplasia/dysplasia
3	Noninvasive low-grade neoplasia (low-grade adenoma/dysplasia)
4	Noninvasive high-grade neoplasia 4.1 High-grade adenoma/dysplasia 4.2 Noninvasive carcinoma (carcinoma in situ) ^a 4.3 Suspicion of invasive carcinoma
5	Invasive neoplasia 5.1 Intramucosal carcinoma ^b 5.2 Submucosal carcinoma or beyond

^aNoninvasive indicates absence of evident invasion.

^bIntramucosal indicates invasion into the lamina propria or muscularis mucosae.

cer (see below). Deep submucosal invasion of a colorectal lesion is defined as ≥ 1 mm (1000 μ m) of submucosal invasion, and is associated with a high risk of residual cancer after endoscopic resection, specifically a high risk of lymph node metastases.¹¹ When endoscopic features of deep submucosal invasion are present, areas exhibiting these features should be biopsied and the patient scheduled for staging studies in anticipation of surgical resection.

Absent the endoscopic features of deep submucosal invasion, most colorectal lesions are candidates for endoscopic resection. There are no endoscopic signs with high sensitivity or specificity for superficial (<1 mm) invasion, however, there are certain endoscopic features associated with a higher risk of superficial submucosal invasion, including large size (≥ 2 cm), depressed or sessile morphology in nongranular lateral spreading tumors (LST-NG), and discrete nodules in granular lateral spreading tumors (LST-G) (see below). Some lesions with these features should be considered for en bloc endoscopic resection because en bloc resection optimizes the pathologic assessment of any lesion, particularly with regard to the depth of invasion.

These points emphasize that optimal management of potentially malignant lesions includes careful endoscopic evaluation and estimation of the degree of invasiveness before resection. Once resection has occurred and cancer is identified by pathology, then the more traditionally discussed issues of whether to proceed with surgery must be

TABLE 3. Narrow Band Imaging International Colorectal Endoscopic Classification

Variable	Type 1	Type 2	Type 3
Color	Same or lighter than the background	Brown relative to background	Brown or black relative to background
Vessels	None or isolated lacy vessels	Brown vessels surrounding white structures	Has areas of disrupted or missing vessels
Surface pattern	Dark or white spots of uniform size	Oval, tubular, or branched white structures	Amorphous or absence of pattern
Most likely histology	Hyperplastic or serrated polyps (sessile serrated polyp)	Adenoma to superficial submucosal invasion	Deep submucosal invasion

addressed. The post-resection management of submucosally invasive lesions optimally utilizes a multidisciplinary approach, with input from the pathologist, surgeon, and sometimes an oncologist and/or radiation oncologist. However, the endoscopist often plays the central role in informed decision-making, frequently serving as the point of contact for the patient and their family.

ENDOSCOPIC SURFACE PATTERN CLASSIFICATIONS

Endoscopic assessment of colorectal polyps and lesions to predict the histologic class (ie, adenoma vs serrated class) and determine the presence of features associated with deep submucosal invasion are important skills for the modern colonoscopist. Endoscopic assessment can be assisted by illumination with wavelengths that enhance blood vessels and delineate surface features (eg, narrow band imaging [NBI]; Olympus, Center Valley, PA and Fujinon Blue Light Imaging; Fujinon, Valhalla, NY) or by post-processing techniques that enhance these elements (eg, Fujinon Linked Color Imaging and Pentax iscan; Pentax Medical, Montvale, NJ). Optical magnification can assist with characterization, if available. Classification systems associating endoscopically visualized surface features with specific histology facilitate prediction of histology by the endoscopist. The descriptions of the polyp and endoscopic classification systems used in the document are provided below.

Narrow band imaging international colorectal endoscopic classification

In 2009, the Colon Tumor NBI Interest Group proposed the NBI International Colorectal Endoscopic (NICE) classification system, which has been validated in subsequent studies as an accurate system to classify polyps as type 1 (serrated class: either hyperplastic or sessile serrated polyp) or type 2 (conventional adenoma).¹² Lesions with disruption of the surface pattern and vessel structure are type 3, which is specific (although not sensitive) for deep submucosal invasive cancer.¹³ The NICE classification system can be used with or without magnification, and does not require use of dye spray^{14,15} (Table 3 and Figure 2).

Japanese Narrow Band Imaging Expert Team classification (modified narrow band imaging international colorectal endoscopic classification)

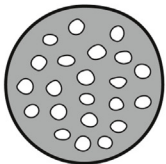

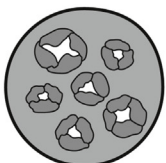
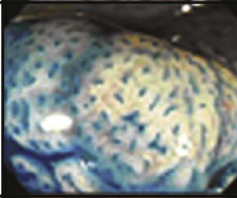
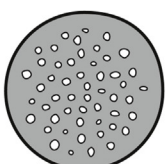
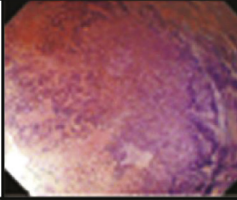

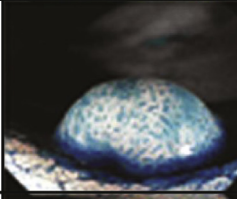

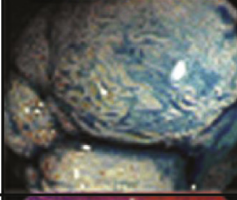

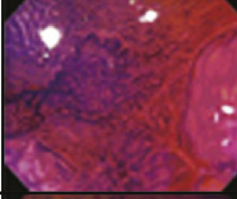


One limitation of the NICE classification is that it is difficult to distinguish among low-grade dysplasia, high-grade dysplasia, and superficial submucosal invasion in type 2 lesions. To address this limitation, the Japanese Narrow Band Imaging Expert Team (JNET) published a new NBI colorectal magnification classification in 2014,¹⁶ which requires magnification endoscopy. JNET maintains NICE types 1 and 3 but divides NICE type 2 into JNET 2a and 2b, with 2b features associated with high-grade dysplasia and superficial submucosal invasion. The classification system is presented in Table 4 and Figure 3.

Kudo pit pattern classification

Used extensively in the East, the Kudo pit pattern classification system has been adopted in the Western world as well.^{17–20} It requires magnification colonoscopy with dye spray (although many Western endoscopists use it without dye spray), and allows for evaluation of malignant polyps through characterization of the pits, which are openings for crypts.^{21–23} As described by Kudo and colleagues,¹⁸ pits are classified into 6 patterns: type I, II, III_L, III_S, IV and V. Type I pits appear as roundish pits; type II pits appear as stellar or papillary pits; type III_S pits are small roundish, tubular pits (smaller than type I), and type III_L are roundish and tubular pits (larger than type I); type IV pits appear as branch-like or gyrus-like pits and type V pits appear as nonstructured pits. Pit pattern type V is further classified as VN (nonstructural) and VI (irregular). Type I and II are characteristic of normal, serrated or inflammatory polyps, whereas pit pattern classes III–V are considered to indicate dysplastic and malignant changes. The classification system is presented in Table 5 and Figure 2.

Other classification systems

Using magnification endoscopy and NBI, there are several colorectal NBI magnifying classifications, such as the Hiroshima classification,²⁴ Sano classification,²⁵ Showa classification,²⁶ and Jikei classification²⁷ used mainly in Asian countries. The BASIC system (for FUJI Blue Light Imaging),²⁸

I		Round pit (normal pit)	
II		Asteroid pit	
III_s		Tubular or round pit that is smaller than the normal pit (type I)	
III_L		Tubular or round pit that is larger than the normal pit (type I)	
IV		Dendritic or gyrus-like pit	
V_I		Irregular arrangement and sizes of III_L, III_s, IV type pit pattern	
V_N		Loss or decrease of pits with an amorphous structure	

Tanaka, et al, *Gastrointest Endosc* 2006;64:604–13

Figure 2. NICE classification Kudo pit pattern classification.

is similar to the NICE classification. Irregular and thickened microvessels, when using NBI, is another way to assess for risk of submucosal invasion with Sano class III A and B, being highly sensitive and specific for estimating depth of submucosal invasion.²⁹ However, several of these systems are not commonly used in the United States.

ENDOSCOPIC MORPHOLOGIC CLASSIFICATION SYSTEMS

Paris classification

Proposed in 2002 at the Paris collaborative meeting,³⁰ the Paris classification is an endoscopic classification of

TABLE 4. Japanese Narrow Band Imaging Expert Team Classification

Characteristics	Colors	Type 2A	Type 2B	Type 3
Vessel pattern	Invisible	Regular caliber Regular distribution	Variable caliber, irregular distribution	Loose vessels areas, interruption of thick vessels
Surface pattern	Regular dark or white spots similar to surrounding mucosa	Regular tubular or branched or papillary	Irregular or obscure	Amorphous areas
Most likely histology	Hyperplastic polyp or sessile serrated polyp	Low grade intramucosal neoplasia	High-grade intramucosal neoplasia/superficial submucosal invasive cancer	Deep submucosal invasive cancer

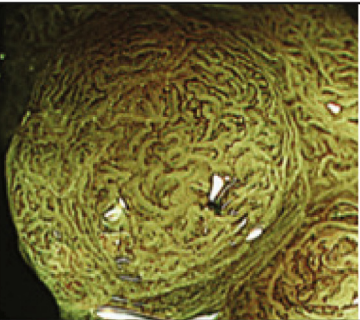
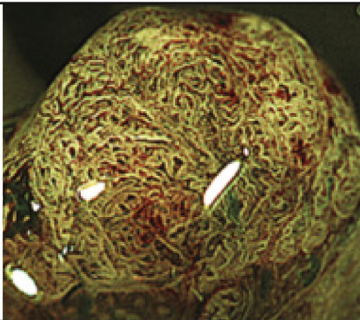
NBI	Type 2B	
	2B-low	2B-high
Vessel pattern	• The thickness and distribution of irregular vessels are uniform	• The diameter and/or distribution of irregular vessels are heterogeneous
Surface pattern	• Irregularly in the pit-like pattern network • Smooth pit-like structure margin without ravaging	• Irregular and destroyed pit-like pattern • Irregular, fluffing, and unclear pit-like structure margin
Examples		

Figure 3. JNET classification.**TABLE 5. Kudo's Classification of Polyp Pit Pattern¹⁸**

Type	Features	Interpretation
I	Round, normal	Normal
II	Asteroid	Hyperplastic
IIIS	Tubular or round pit smaller than normal pit	Tubular adenoma
IIIL	Tubular or round pit larger than normal pit	Tubular adenoma
IV	Gyrus/dendritic	Tubulovillous or villous adenoma
VI	Irregular arrangement	Neoplastic, invasive
VN	Loss or decrease of pits with amorphous structure	

superficial colorectal lesion morphology, whereby a lesion is superficial when its endoscopic appearance suggests that the depth of penetration in the digestive wall is not more than into the submucosa, that is, there is no infiltration of the muscularis propria. The Paris classification describes 3 major superficial morphologies with subtypes. Lesions are classified as polyps (type 0–I), which include both

pedunculated (0–Ip) and sessile (0–Is) morphologies; or flat lesions (type 0–II), which consist of slightly elevated (0–IIa), flat (0–IIb), and slightly depressed (0–IIc) morphologies. Lesions with the third major morphology, excavated (0–III), are rarely seen in the colon. The classification system is presented in Figure 4. We present differences in management and outcomes based on

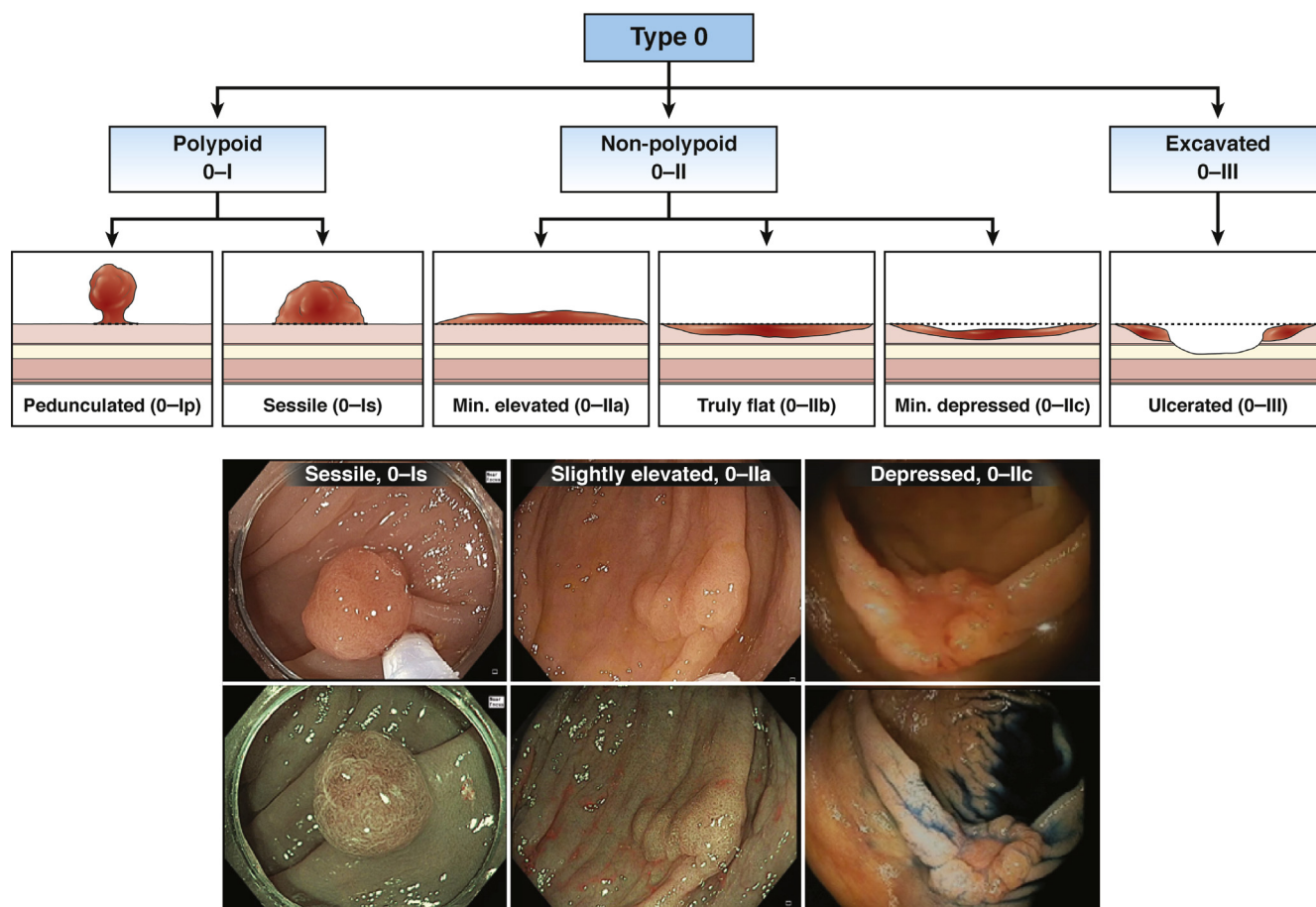


Figure 4. Paris classification of polyp morphology.

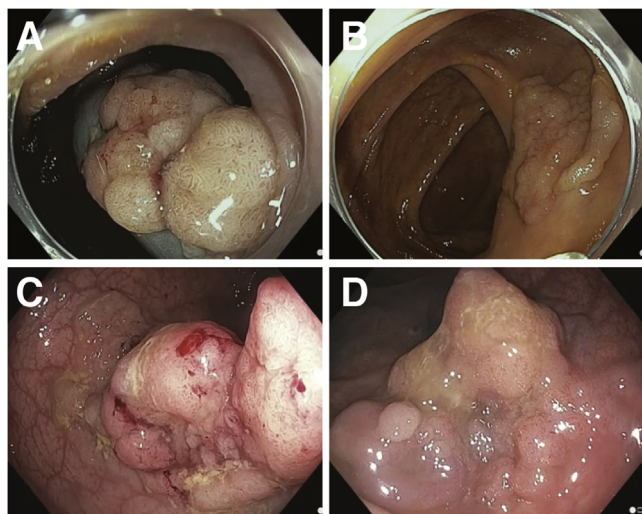


Figure 5. Granular laterally spreading tumors (LST-G). (A, B) Nodular surface. (C, D) mixed nodular morphology.

morphologies in the key questions, where applicable. It is important to acknowledge that interobserver agreement of the Paris classification among expert endoscopist is modest.³¹

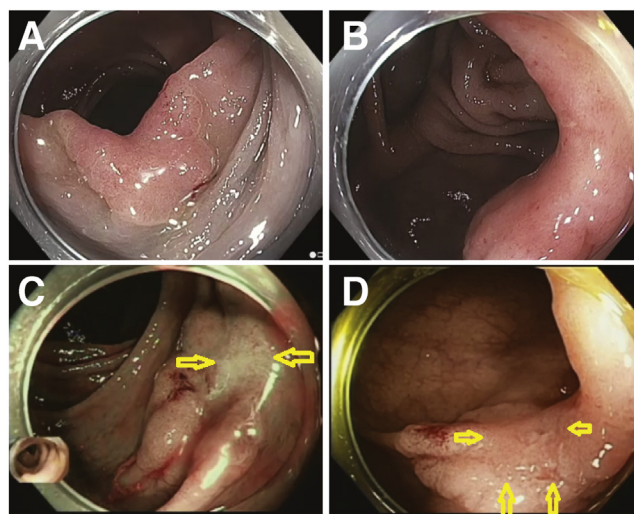


Figure 6. Nongranular laterally spreading tumors (LST-NG). (A, B) Smooth surface. (C, D) Pseudodepressed.

Laterally spreading tumor (lesion)

Okamoto et al³² described polyps in the colorectum that are > 10 mm, flat (0-II), or sessile (0-Is) shape, and extend laterally (in contrast to vertically) along the

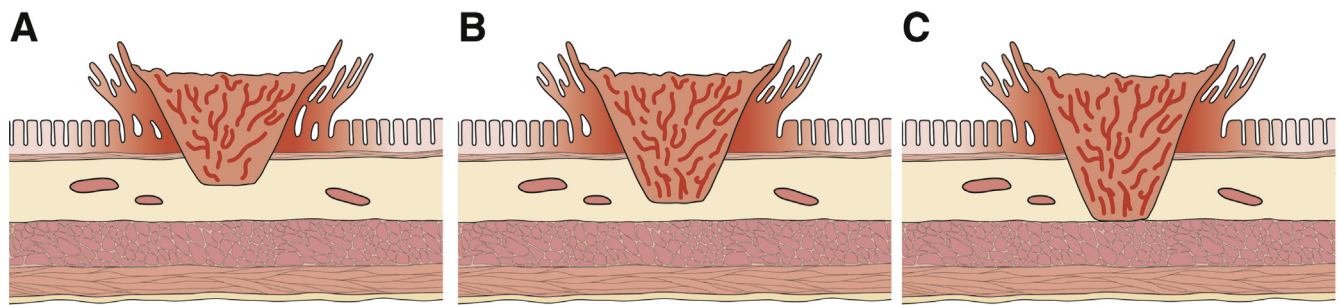


Figure 7. Kikuchi classification.

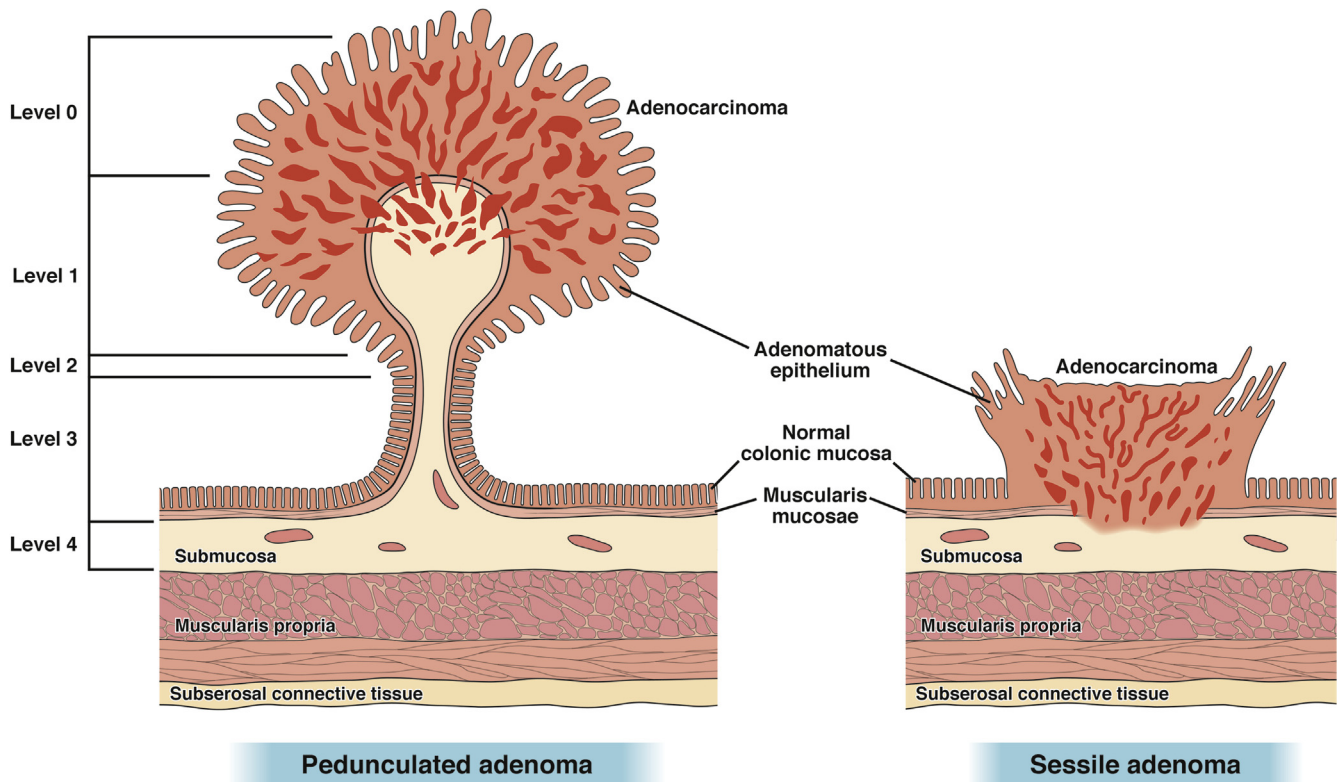


Figure 8. Haggitt classification.

colonic wall, as LSTs or lateral spreading lesions. These lesions are further classified into 2 distinct phenotypes, LST-G, which has a nodular surface, and LST-NG, which have a smooth surface (Figures 5 and 6). LST-G can be subtyped by the nodular surface and are comprised of lesions with homogeneous even-sized nodules and lesions with nodules of mixed sizes known as mixed LST-G. LST-NG have a smooth surface and are comprised of the flat elevated and pseudodepressed subtypes.

The morphologic sub-classifications of LSTs facilitate the endoscopic removal plan, as they inform about the risks of submucosal invasion and submucosal fibrosis. For example, LST-G with even-sized nodules tend to

grow laterally to very large diameters with a low risk of developing submucosal invasion (<2%) or significant fibrosis regardless of size,³³ whereas LST-G with mixed-sized nodules have a higher risk of submucosal invasion (7.1% for lesions <20 mm and 38% for those >20 mm),³⁴ with the point of invasion usually located under the largest nodule. In such lesions, it is preferable to remove the largest nodule (and any nodule suspicious to harbor more advanced pathology) in one piece when feasible, in order to optimize histologic assessment. LST-NG have a high risk of submucosal invasion: 27.8% and 41.4% in nongranular pseudodepressed LSTs 10–19 mm and 20–29 mm, respectively, and 6.4% and 10.4% in nongranular

flat elevated LSTs 10–19 mm and 20–29 mm, respectively.³⁵ In such lesions, the points of invasion are typically multifocal. In addition, LST-NG lesions often have submucosal fibrosis that can make their removal with simple snare resection or even standard endoscopic mucosal resection (EMR) more technically challenging.

Nonlifting sign

The nonlifting sign for sessile polyps was described by Uno et al,³⁶ whereby fluid injected under the polyp fails to lift it. The nonlifting sign may be due to deep submucosal invasion³⁷ in lesions without prior endoscopic manipulation or attempted resection. The nonlifting sign may also be the result of fibrosis from prior biopsy, cautery, or tattoo, in which case it does not reflect deep submucosal invasion and is not a contraindication to endoscopic resection.³⁸

HISTOLOGIC CLASSIFICATION SYSTEMS FOR DEPTH OF CANCER INVASION

Kikuchi and Kitajima classification systems for depth of submucosal invasion

Accurate measurement of the depth of invasion in malignant polyps generally requires specific handling of the pathology specimen, that is, pinning the cut surface of the specimen to a stiff material before immersion into formalin. Pinning the specimen enables the cut sections to be properly oriented for evaluation by the pathologist (ie, at right angles to the plane of the resection). For sessile malignant polyps, the Kikuchi classification describes the depth of invasion by dividing the submucosa into three levels (SM1–3). SM1, 2, and 3 denote invasion of cancer into the first one-third, second one-third, and the deepest one-third of the submucosa, respectively.³⁹ The Kikuchi classification system is presented in Figure 7. The difficulty in implementing the Kikuchi system is that the entire submucosa is not typically present in endoscopic resection specimens. For that reason, the Kikuchi system has been largely replaced by measuring the depth of submucosal invasion with an optical micrometer. An invasion depth of < 1 mm is called “superficial submucosal invasion” and is associated with a very low risk of lymph node metastasis (0%–4%), provided that other adverse histologic features are absent. An invasion depth of ≥1 mm (“deep submucosal invasion”) is associated with a substantial risk of residual disease in the bowel wall or lymph nodes after endoscopic resection (10%–18%),¹¹ and is generally an indication for adjuvant surgical resection.

Haggitt classification of depth of submucosal invasion

In 1985, Haggitt et al⁴⁰ proposed a classification system for depth of cancer invasion in polyps. The Haggitt classification is shown in Figure 8. This system is most

useful for pedunculated polyps. Neoplasia within pedunculated polyps are classified as levels 0–4. In level 0, dysplastic elements are limited to the mucosa. Levels 1–4 have submucosal invasion but are based on the invasive portion in the head, neck, and stalk of the pedunculated polyp. Level 1 denotes cancer invasion into the submucosa, but is limited to the head of the pedunculated polyp. Level 2 denotes cancer cells reaching the neck of the pedunculated polyp and, in level 3, cancer cells invade the stalk. Level 4 indicates cancer cells invading the submucosa below the stalk, but not the muscularis propria of the pedunculated polyp. All malignant nonpedunculated lesions that by definition have submucosal invasion are classified as Haggitt level 4. Because endoscopists transect pedunculated polyps through the stalk, it limits the clinical relevance of the Haggitt classification in assessment of malignant polyps resected endoscopically.

KEY QUESTIONS, RECOMMENDATIONS, AND DISCUSSION

Question 1a: Which endoscopic features in a colorectal polyp predict deep submucosal cancer?

Question 1b: When deep submucosal cancer is suspected, how should nonpedunculated and pedunculated polyps be managed?

Recommendation 1a: We recommend that both pedunculated and nonpedunculated polyps with the following features be considered to have deep submucosal invasion: NICE classification type 3 or Kudo classification of type V (VN and VI).

Strong recommendation; high-quality evidence

Recommendation 1b: Nonpedunculated lesions with these features should be biopsied (in the area of surface feature disruption), tattooed (unless in or near the cecum), and referred to surgery. Pedunculated polyps with features of deep submucosal invasion should undergo endoscopic polypectomy.

Weak recommendation; low-quality evidence

Discussion

Nonpedunculated (0–Is and 0–II) lesions. Endoscopic features of deep submucosal invasion are highly specific. Hayashi et al¹³ performed a validation of the

NICE 3 features for prediction of deep submucosal invasion using 80 images and a panel of 5 expert endoscopists, and reported that presence of any 1 of the 3 deep submucosal invasive carcinoma (color, vessels, or surface pattern) had 94% accuracy and 96% negative predictive value.¹³ Similarly, type VN pit pattern in the Kudo classification indicates deep submucosal invasion. A 2011 prospective multicenter, observational study by the Australian Colonic Endoscopic resection study group evaluated 479 patients with large (≥ 20 mm) polyps and found invasion of the deep submucosa in 56% (14 of 25) of polyps with pit pattern type V compared to only 4%–5% in lesions with other pit patterns.⁴¹ In their follow-up study⁴² evaluating 2693 lesions, Kudos pit pattern V was the strongest factor associated with overt submucosal invasive cancer (odds ratio [OR], 1.42; 95% confidence interval [CI], 8.57–23.4) and predicted cancer with 97% specificity, 40% sensitivity, and 93% diagnostic accuracy. A meta-analysis of 20 studies evaluating diagnostic accuracy of Kudo pit pattern, performed a sub-group analysis of 1623 colorectal lesions from 4 studies that reported the number of lesions in each pit pattern by pathology results, and reported a pooled sensitivity of 90.4% (95% CI, 79.7–95.7) and pooled specificity of 88.4% (95% CI, 82.9–92.3).²³ When nonpedunculated lesions with NICE 3 or Kudo VN features are encountered, biopsy should be directed to the region of surface feature disruption, tattooed if not in or near the cecum, and the patient directed to surgery. NICE 3 and Kudo VN features are often associated with surface ulceration and irregularity. In 1 series, the risk of deep submucosal invasion in 181 lesions that were LST-NG with depression/ulceration was 12.5%, 32.4%, and 83.3% for lesions of size 10–19 mm, 20–29 mm, and ≥ 30 mm, respectively.³⁵ The nonlifting sign for sessile polyps is also associated with deep submucosal invasion,³⁷ with positive predictive value of approximately 80%.³⁸ However, lesions may also not lift because of submucosal fibrosis from prior biopsy, cautery, or tattoo.⁴³

Pedunculated (0-Ip) lesions. Pedunculated polyps with features of deep submucosal invasion are candidates for endoscopic resection, as the overall histological features may still be favorable.⁴⁴ All pedunculated lesions should be resected en bloc through the stalk and bivalved through the polyp head and stalk by pathology. An accurate histologic diagnosis is key to accurate staging and management (see question 2).

Figure 9 provides an algorithm for recognition and management of malignant polyps

Question 2a. Which endoscopic features predict risk of superficial submucosal invasion in a sessile polyp?

Question 2b. What is the optimal endoscopic method of resection for sessile and pedunculated malignant polyps with superficial submucosal invasion?

Recommendation 2a: LST-NG morphology with sessile shape or depression, and LST-G with a dominant nodule predict a higher risk of submucosally invasive cancer.

Weak recommendation; moderate-quality evidence

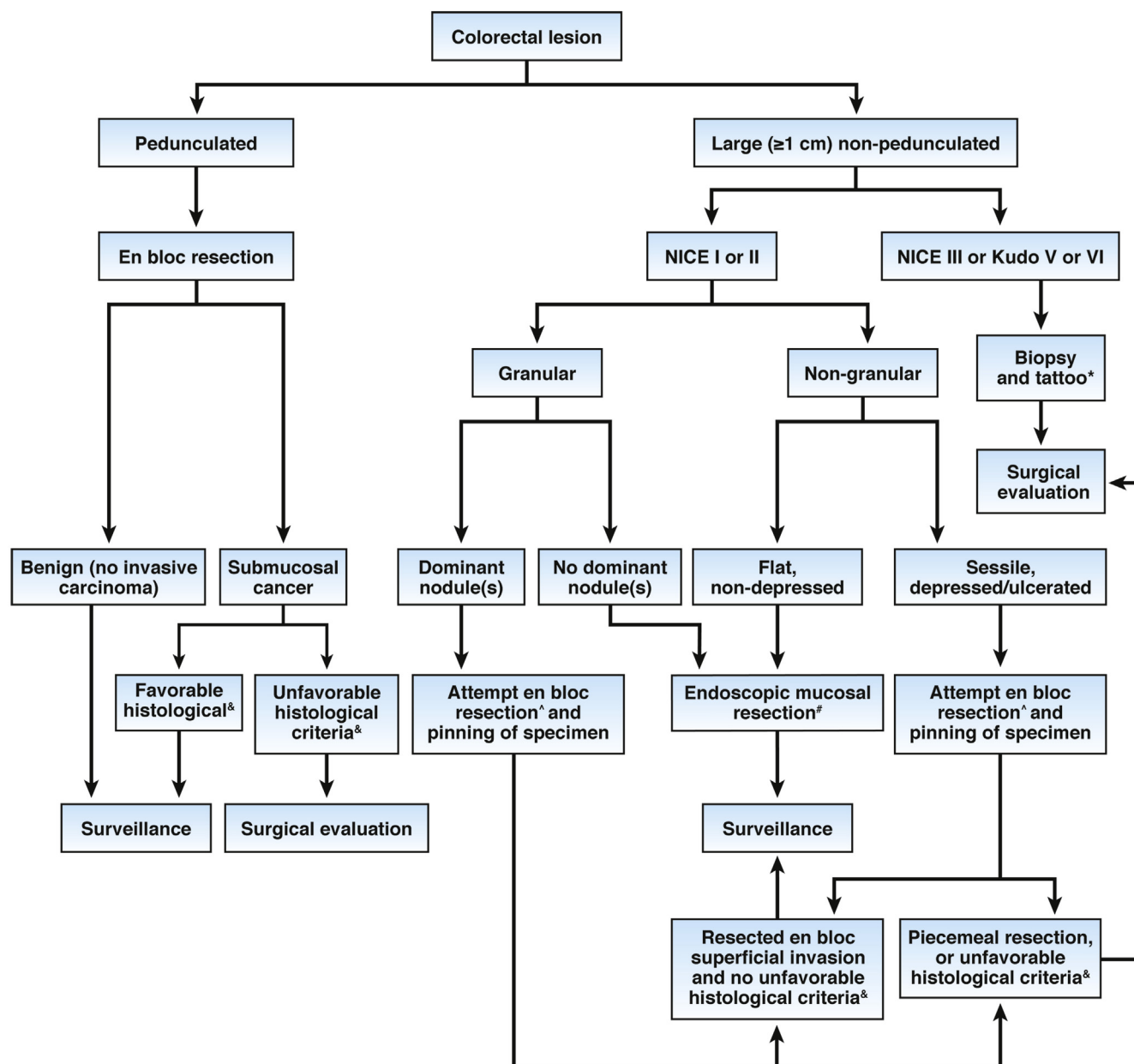
Recommendation 2b: We recommend that such lesions be considered for en bloc endoscopic resection, instead of piecemeal resection, when feasible and based on local expertise. In the case of LST-G with a dominant nodule, at least the nodular area should be considered for en bloc resection. All pedunculated polyps, even if large, should be resected en bloc.

Weak recommendation; low-quality evidence

Discussion

In a nonpedunculated lesion, if endoscopic features of deep submucosal invasion are absent, the next step is to evaluate the polyp for other morphologic features that predict an increased risk of superficial submucosal invasion. Consideration should be given to resecting the lesion en bloc for precise pathologic assessment if the morphologic features discussed below are present.

Polyps with depressed (0-IIc) morphology are often associated with invasive cancer even when small.^{45–49} One study found that of 3680 lesions, 61% of 0-IIc lesions had submucosal invasion.³⁰ Assessing the morphology of 2277 ≥ 20 mm lesions, Burgess et al⁴² reported that compared with 0-IIa, lesions with 0-Is (OR, 2.73; 95% CI, 1.64–4.55) and 0-IIa+0-Is (OR, 2.49; 95% CI, 1.52–4.08) morphology were associated with submucosal invasive cancer. The authors also reported that lesions with a 0-IIc component had a high specificity (95.9%) and diagnostic accuracy (90.3%) for submucosal invasive cancers but low sensitivity (21%). In combining Paris classification and gross morphology, the authors were able to improve the prediction of covert or occult submucosal invasive cancer (defined as lacking endoscopic features of submucosally invasive cancer, such as a depressed or ulcerated component, or an area of disrupted surface pit pattern), such that 0-Is nongranular and 0-IIa+Is nongranular lesions had a substantially higher risk of occult submucosal invasive cancer (OR, 22.5; 95% CI, 7.07–71.6 and OR, 14.4; 95% CI, 4.53–45.5, respectively). Type 2B lesions in the JNET classification have a higher risk of superficial submucosal invasion, where en bloc resection should be considered, if feasible. Whether JNET can be applied accurately without full optical magnification remains uncertain.



*Tattoo not required for cecal polyps. Tattoo should be targeted near the base of the polyp as well as to the opposite lumen wall.

#Piecemeal if size >20mm.

^If low likelihood of complete removal, the areas near the polyp should be tattooed and resection should be referred to endoscopists or centers with more experience at endoscopic mucosal resection.

&Unfavorable histologic criteria are: depth of submucosal invasion >1mm, polypectomy margins positive for tumor cells, poor grade of differentiation, tumor budding or lymphovascular invasion.

Figure 9. Algorithm for approach to malignant polyp assessment and management.

Studies on diagnostic accuracy of the JNET classification are ongoing, and early studies show promise.¹⁶

Neither lesion size nor location alone have enough discriminant value to reliably predict risk of submucosal invasion, but combined with other endoscopic features (see

above), these factors may warrant consideration. Multiple studies have demonstrated that risk of submucosal invasion is higher with lesions ≥ 20 mm. In their 1997 study, Nusko et al⁵⁰ examined 11,188 adenomatous lesions and invasive carcinoma was found in 1313 (11.7%). The odds

of submucosal invasion was 4.27 (95% CI, 3.06–5.96) in lesions >16 mm, rising to an OR of 10 (95% CI, 6.97–14.56) in lesions >35 mm in size compared to polyps ≤5 mm in which no cancer was detected. Consono et al⁵¹ also found a correlation between increase in lesion size and risk of malignancy. They reviewed 1354 polypectomies, 28 (2.1%) had invasive carcinoma and 71% of the invasive carcinomas were >20 mm in size.⁵¹ Some of the largest nonpedunculated lesions in the colon are the LST-G. These lesions have a low risk of submucosal invasion, which presumably allows them to grow laterally for large distances while remaining benign. Hurlstone et al⁵² published a prospective series of 82 LST that were removed with EMR. They reported that LST-NG were more likely to be present in the right colon and have submucosal invasion compared with LST-G. In another study evaluating 511 LSTs, LST-G lesions showed a 7% risk of submucosal invasion compared with 14% in LST-NG lesions.⁵⁴ Among LST-G lesions, those with nodules >10 mm were more strongly associated with submucosal invasion (29.8% vs 2%; $P < .0001$).⁵⁴ Another study reported the risk of deep submucosal invasion in LST-G with mixed-sized nodules to be substantially higher (7.1% for lesions <20 mm and 38% for >30 mm) compared with LST-G without nodules (<2%).⁵⁴ A Japanese study of 1363 LSTs of at least 10 mm reported higher submucosal invasion with pseudodepressed (see Figure 5C) LST-NG lesions compared with flat elevated LST-NG lesions (42.1% vs 6.1%; $P < .01$).⁵³

Malignant polyps are most often located in the right colon but also have a predilection for the rectosigmoid colon. Seitz et al⁵⁴ found that 61 of 116 malignant polyps in their study were in the sigmoid colon, with 41 of the remaining 55 malignant polyps being in the rectum. In another study, Geraghty et al⁵⁵ had similar findings, with 58 of 81 malignant polyps in their study found in the sigmoid colon. In another study,⁵⁰ 32.9% of malignant polyps were in the rectum with the next highest percentage at 17.9% found in the right colon (cecum to splenic flexure). This was in concordance with another study in which 103 of 479 malignant polyps (21.5%) with superficial and deep submucosal invasion were found in the right colon.⁴¹ In a recent analysis of 2277 lesions ≥20 mm, increasing size (per 10 mm) and rectosigmoid location were predictive of lesions with overt (ie, with endoscopic features) and covert (ie, without endoscopic features) submucosal invasive cancer (OR, 1.12; 95% CI, 1.01–1.23 and OR, 1.91; 95% CI, 1.31–2.79, respectively).⁴² The rectal wall is relatively thick compared with the colon, and part of the rectum is below the peritoneal reflection. Factors like these make en bloc resection in the rectum relatively safe compared with the colon. Another important reason why location in the colon impacts the discussion of resection methods (ie, en bloc vs piecemeal) is that the morbidity of rectal operations used to follow-up endoscopic resection of ma-

lignant polyps is greater than the morbidity of colonic resections. The rationale for en bloc resection of rectal lesions with an increased risk of superficial submucosal invasion is greater than for colonic lesions.

In summary, endoscopic features associated with an increased risk of superficial submucosal invasion in the absence of endoscopic features of deep submucosal invasion include LST-NG morphology (particularly if there is depressed shape), and LST-G morphology with dominant nodules. If these lesions are resected en bloc, and the resected specimen is sectioned properly in the pathology department, it will be possible to accurately measure the depth of any submucosal invasion. Because superficial submucosal invasion is associated with a very low risk of residual cancer in the bowel wall or lymph nodes after endoscopic resection, patients with en bloc resection and superficial submucosal invasion may be able to avoid surgical resection that would otherwise be indicated for the same lesion after piecemeal resection. Fortunately, LST-NG with unfavorable morphology are often relatively small-diameter lesions, and may be candidates for en bloc EMR resection. In cases of large LST-G with a dominant nodule, a commonly used approach by experts is to resect the nodule en bloc and send it to pathology separately, with the remainder of the lesion removed piecemeal. If en bloc endoscopic resection is beyond the skillset of the endoscopist, these patients should be referred to a dedicated center with appropriate endoscopic expertise. Endoscopic submucosal dissection has been shown to be associated with the highest rates of en bloc resection and is available in some centers in the United States. Compared with EMR, it has a higher risk of complications, including perforation, cost related to more frequent post-procedural hospitalization, longer learning curve, and poor reimbursement. Although endoscopists should be aware of endoscopic features associated with superficial submucosal invasion and the rationale for en bloc resection, the actual approach to endoscopic resection will reasonably take into account lesion size, morphology, location in the colon, and the availability of local expertise and resources to accomplish en bloc resection.

Question 3. How should polyp specimens with features suggestive of submucosal cancer and resected en bloc be prepared for submission to pathology?

Recommendation: We recommend that specimens with features associated with submucosally invasive cancer that are removed en bloc be handled in ways to optimize specimen orientation and pathologic assessment.

Weak recommendation; low-quality evidence

Discussion

The request to pathology should include the location, size, and morphology (sessile vs pedunculated) of the polyp. Polyps that are resected en bloc with an increased risk of cancer should be pinned to a firm surface before submersion in formalin and sectioned in pathology perpendicular to the plane of endoscopic resection. [Figure 10](#) shows the optimal handling technique for large sessile polyps. The following considerations apply to pedunculated and sessile polyps.

For resected pedunculated polyps, the lesion should be retrieved through the suction channel or using a net or snare with withdrawal of the scope. Large pedunculated lesions resected en bloc should not be cut to facilitate removal through the suction channel. After submission to pathology, the lesion should be bisected so that sections are cut through the entire polyp head and stalk. This orientation allows the location of any cancer in relation to the stalk and the resection line to be evaluated. The cautery burn on the stalk generally provides a good marker for the pathologist to orient the specimen for sectioning. If the stalk retracts promptly, placing a pin into the stalk before placing the specimen in formalin can ensure the pathologist identifies the stalk and orients the specimen properly for sectioning. If the sections are cut without proper orientation, it will not be possible to make a full assessment of features associated with residual cancer in the patient, and surgery may be required. In the unfortunate instance in which the polyp head is resected piecemeal, submitting the stalk with any attached polyp head separately to the pathologist may allow proper sectioning of the all-important stalk and most adjacent polyp tissue.

For nonpedunculated lesions suspected of having submucosal invasion removed en bloc via EMR or endoscopic submucosal dissection, the fresh specimen should be pinned onto a firm surface with peripheral stainless-steel pins around the entire circumference and fixed in 10% formalin ([Figure 10](#)).⁵⁶ Fixing the specimen without pinning can cause tissue shrinkage and curling of the specimen, preventing proper orientation and sectioning in pathology.^{55,56} The lesion should be sectioned in a plane perpendicular to the plane of resection to achieve proper pathologic orientation, and typically the entire lesion is sectioned at 2-mm intervals. Poor specimen orientation can also mean that the pathologist might have trouble finding the lateral and vertical margins,⁵⁷ and consequently, inaccurate measurement of depth of invasion and assessment of margin involvement.

Question 4a. Which histologic features in nonpedunculated malignant polyps are associated with lymph node metastasis and therefore an increased risk of local or regional recurrence?

Question 4b. Which histologic features in pedunculated malignant polyps are associated with lymph node metastasis and therefore an increased risk of local or regional recurrence?

Recommendation 4a: We recommend that non-pedunculated malignant polyps be considered high risk for residual or recurrent cancer if they have any of the following features: poor tumor differentiation, lymphovascular invasion, submucosal invasion depth >1 mm, tumor involvement of the cautery margin, or tumor budding.

Strong recommendation; moderate evidence

Recommendation 4b: We recommend that pedunculated malignant polyps be considered at high risk of residual or recurrent cancer if they have any of the following features: poor tumor differentiation, lymphovascular invasion, tumor within 1 mm of the resection margin

Strong recommendation; moderate evidence

Discussion

Histologic features of the resected polyp can have prognostic value in predicting lymph node metastasis (LNM) and local, regional or distant CRC. Most studies evaluating histologic features that predict LNM include patients that have undergone surgical resection of pT1 tumors and have evaluable lymph nodes and histologic details of the tumor. Studies that evaluate presence of cancer at the local, regional, or distant site include patients that underwent endoscopic resection for malignant polyp and developed local, regional, or distant CRC during follow-up of variable duration. The term *recurrence* is often used in these studies for the CRC, even though follow-up may be very short and the cancer may be a residual cancer at the local site.

Identifying features associated with LNM, both endoscopically and histologically, is very important as it helps inform which patients should undergo surgery. Unfavorable histologic features relevant to both pedunculated and nonpedunculated (sessile, flat, nonpolypoid) malignant polyps include poorly differentiated adenocarcinoma, lymphovascular invasion, and presence of tumor budding.⁵⁸ For pedunculated malignant polyps alone, resection margin of <1 mm is an unfavorable histologic feature, and for nonpedunculated polyps, the width of resection is important. These are discussed below. Bosch et al⁵⁹ performed a systematic review of studies that included patients with malignant polyps (defined in the paper as pT1 CRC, pedunculated and nonpedunculated not specified, that underwent surgical resection and had complete lymph node status assessed to determine histologic predictors of lymph node metastasis at the time of surgery. The analysis included 17 studies (n =

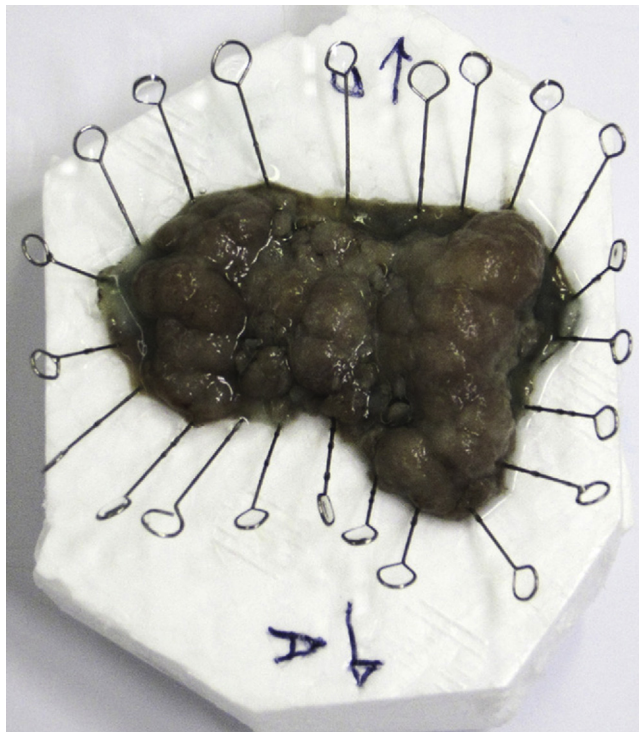


Figure 10. Optimal handling of large sessile polyp after en bloc resection. A formalin fixed specimen with steel pins on the borders and orientation of O (oral) and A (anal) to maintain margin status.

3621 patients) and the strongest independent predictors of LNM were lymphatic invasion (RR, 5.2; 95% CI, 4.0–6.8), submucosal invasion >1 mm (RR, 5.2; 95% CI, 1.8–15.4), tumor budding (RR, 5.1; 95% CI, 3.6–1 and RR, 5.2; 95% CI, 1.8–15.4), and tumor budding (RR, 5.1; 95% CI, 3.6–2). Mou et al⁶⁰ conducted a systematic review that included 5 studies of patients after resection of nonpedunculated malignant polyps only (sessile or nonpolypoid) (n = 1213 patients). The risk of LNM was 13% (95% CI, 11.5%–15.4%). Characteristics associated with absence of LNM were <1 mm submucosal invasion (RR, 1.15; 95% CI, 1.11–1.18), well-differentiated histology (RR, 3.99; 95% CI, 1.18–13.46 vs poorly differentiated), absence of lymphatic and vascular invasion (RR, 1.26; 95% CI, 1.18–1.34 and RR, 1.16; 95% CI, 1.07–1.24, respectively), and absence of tumor budding (RR, 1.16; 95% CI, 1.08–1.25). Miyachi et al⁴⁹ reviewed 653 patients with surgically resected pT1 CRCs with complete lymph node evaluation. The reported rate of LNM was 9.2%. Factors associated with LNM included lymphovascular infiltration (OR, 9.84; 95% CI, 3.42–28.3), tumor budding (OR, 1.80; 95% CI, 1.01–3.21), and poor differentiation (OR, 2.31; 95% CI, 1.25–4.27). The National Comprehensive Cancer Network (NCCN) guidelines recommends the following 4 features as high risk of LNM and need for surgery: positive margins (<1 mm or indeterminate), histologic grade 3 or 4, lymphovascular invasion, and tumor

budding.⁹ It should be noted that depth of invasion and resection margin are 2 distinct concepts. Depth of invasion is most relevant to nonpedunculated malignant polyps, and for pedunculated polyps, the resection margin is important. These and other histologic risk factors are discussed below.

Depth of submucosal invasion

In nonpedunculated malignant polyps, the depth of submucosal invasion is an important determinant of lymph node metastasis and need for surgical resection. The assessment of depth of invasion requires en bloc resection, proper specimen handling by the endoscopist and the pathologist, and use of an optical micrometer by the pathologist. Many studies have described the depth of submucosal invasion as a predictor of LNM.^{59,61,62} For nonpedunculated polyps, the depth of invasion (as measured by an optical micrometer) of ≥ 1 mm is widely accepted as the cutoff for deep submucosal involvement and increased risk of LNM. In a meta-analysis that pooled studies looking at risk factors for LNM (n = 7376 polyps), deep submucosal invasion (>1 mm) was an independent risk factor for LNM (OR, 3.00; 95% CI, 1.36–6.62).¹¹ In a retrospective study across 6 hospitals in Japan, the odds of LNM with submucosal invasion ≥ 1 mm was 5.4 (95% CI, 1.62–17.93).⁶¹ In their systematic review of 23 studies with 4510 patients, deep submucosal invasion (>1 mm) was a significant risk factor for LNM (OR, 3.87; 95% CI, 1.50–10.00).⁶³ A systematic review of 13 studies with 7066 patients with submucosal invasion who underwent surgery and lymph node evaluation reported increased risk of LNM with \geq SM2 (Kikuchi classification) or ≥ 1 mm invasion (OR, 3.00; 95% CI, 1.36–6.62).¹¹

The Kikuchi classification is also well studied.³⁹ Malignant invasion confined to the superficial third (SM1) has a low risk of LNM (1%–3%) and can be managed with endoscopic resection alone with close surveillance, and with SM2 and SM3, the risk of LNM is 8% and 23% respectively, warranting surgical resection. However, because muscularis propria is not present normally in an endoscopically resected specimen, a definitive SM level often cannot be determined.

The Haggitt classification is used for measuring depth of invasion in a pedunculated malignant polyp, where level 4 is associated with high risk of LNM.⁶⁴ One study evaluated 150 polyps with submucosal cancer that underwent surgery and lymph node evaluation.⁶⁵ Overall, 6% of the pedunculated polyps had LNM. Pedunculated polyps with invasion into the submucosa of the head, neck, or stalk (level 1–3) had no LNM, and invasion into the submucosa below the stalk (level 4) had 27% prevalence of LNM. Because pedunculated polyps are usually transected through the stalk and not below it, in clinical practice it is more common to rely on the resection margin (see below) in malignant pedunculated polyps than on the Haggitt classification.

Polypectomy resection margin

The width of any margin between the cancer and the resection margin at the polypectomy site is an important histologic risk factor for the presence of LNM and recurrence for both pedunculated and nonpedunculated malignant polyps. In 1984, Morson et al⁶⁶ reported no recurrence of cancer at 5 years of follow-up after endoscopic polypectomy of 60 malignant polyps with a clear (tumor-free) margin of resection. However, subsequent studies have advocated a margin of at least ≥ 1 mm⁶⁷ and ideally 2 mm.⁶⁸ For pedunculated polyps, the proximity of the tumor from the resection margin is a much more important histologic risk factor.⁶⁹ The recurrence rate of local cancer and/or LNM is reported to be 0% to 2% for all malignant polyps with margins ≥ 1 mm,^{58,70} but increased to 21%–33% with resection margin <1 mm in patients with malignant polyps who undergo endoscopic resection followed by surgical resection. A 2012 study⁵⁷ reported outcomes of 147 patients undergoing EMR followed by surgical resection. Positive polypectomy margins were significantly associated with residual malignancy: 16% of patients had residual disease when the margin of resection was <1 mm; 21% when margin of resection was indeterminate, and 0% when margin of resection was ≥ 1 mm. A study evaluating 85 patients retrospectively reported similar findings, that the odds of adverse outcome (defined as residual cancer in a resection specimen and local or metastatic recurrence in the mean follow-up period of 67 months) was 20.2 (95% CI, 2.6–998) with a margin of resection that was not cancer-free or indeterminate.⁵ In a systematic review of 31 studies with 1900 patients, Hassan et al⁶² reported that a positive resection margin was an important risk factor for unfavorable outcomes (residual disease, recurrent disease, lymph node metastasis, hematogenous metastasis, and mortality) with pooled OR of 22 (95% CI, 10.3–46.6). European guidelines define positive polypectomy margins of malignant polyps when malignant cells are detected <1 mm of the margin.⁷¹ However, polypectomy artifacts can cause discrepancies between positive margins and true tumor remnants. Boenicke et al⁷² studied 105 individuals that underwent endoscopic resection of malignant polyps followed by surgery and reported that although 63% of resection margins were not deemed tumor-free, subsequent surgical specimens showed residual carcinoma in only 2.8%.

Grade of tumor differentiation

The risk of LNM is higher with poorly differentiated tumors vs moderately or well-differentiated ones. Choi et al¹¹ performed a meta-analysis of 13 studies with 7066 individuals who underwent radical surgery for early CRC and found that poorly differentiated carcinoma was indicative of LNM (OR, 8.27; 95% CI, 4.6–14.6). Another meta-analysis summarizing 31 studies and including 1900 patients with malignant polyps that were managed with

either endoscopic or surgical resection corroborated this, showing an association between poorly differentiated histology and residual disease (OR, 2.2; 95% CI, 1.01–4.8) and LNM (for the subgroup that underwent surgical resection and lymph node dissection) (OR, 3.9; 95% CI, 2–7.9).⁶²

Lymphovascular invasion

Lymphovascular invasion in the endoscopic resection specimen is another independent risk factor for LNM, although the definition used by pathologists varies and the inter-observer variability is high.⁷³ One series summarizing 16 case series with 351 patients who underwent surgery for a malignant polyp reported that 45% of patients with lymphovascular invasion had LNM.⁷⁴ Choi et al¹¹ included 8 studies in their systematic review and reported an increased risk of LNM in patients with lymphovascular invasion (OR, 5.47; 95% CI, 2.46–12.17). Kitajima et al⁶¹ published their retrospective study on 865 patients who had undergone surgical resection at 6 institutions in Japan. Multivariate analysis of risk factors for LNM showed that lymphatic invasion in the submucosa was an important risk factor (OR, 4.7; 95% CI, 2.77–7.95). A meta-analysis by Hassan et al evaluating for predictive factors of LNM provides further evidence by looking at 31 studies with 1900 patients and showing that patients with submucosal vascular invasion had a higher risk of LNM with a reported OR of 7 (95% CI, 2.6–19.2).⁶²

Tumor budding

Tumor budding is defined as foci of isolated cancer cells or a cluster of 5 or fewer cancer cells at the invasive margin of the polyp. Typically, tumor budding is calculated in a hotspot with the highest density of tumor budding. Historically, there has been no consensus on a cutoff value or definition and many pathologists do not routinely report tumor budding. It is likely that in the past these were reported as poorly differentiated carcinoma. However, in 2009, a study from Japan evaluated 98 malignant polyps removed by colonoscopic polypectomy at a tertiary institution in Japan during an 8-year period⁷⁵ and reported tumor budding was a risk factor for LNM, although the CIs were wide (OR, 20.1; 95% CI, 1.6–246.5).⁷⁵ A meta-analysis of 13 other studies ($n = 7066$) also reported that tumor budding was an independent risk factor for LNM (OR, 4.59; 95% CI, 3.44–6.13).¹¹ A recent study with 290 patients with endoscopically resected malignant polyps who underwent surgical resection also reported tumor budding as one of the risk factors for LNM, found in 42% of tumors with LNM compared with 18% in LNM-negative tumors (OR, 2.3; 95% CI, 1.1–5.0).⁷⁶ Recently, recommendations of an international Tumor Budding Consensus Conference were published in a consensus agreement defining tumor budding and specifically separated tumor

budding from tumor grading.⁷⁷ The international group achieved consensus on important statements, including that tumor budding is defined as a single tumor cell or a cell cluster consisting of 4 or fewer tumor cells; tumor budding is an independent predictor of LNM in malignant polyps and should be assessed in addition to other clinicopathologic features in a multidisciplinary setting and be part of the CRC reporting system. Tumor budding reporting is recommended by AJCC and the updated 2018 College of American Pathologists cancer protocol, although not required for synoptic (required core elements) reporting.

The presence of any of the histologic factors described here is associated with a higher risk of residual cancer after endoscopic resection of a malignant polyp and should be considered a general indication for adjuvant surgical resection, although this decision must be considered in the context of the individual patient's surgical risk and comorbidities. In addition, any cancer in a nonpedunculated or pedunculated lesion resected piecemeal or a pedunculated polyp that could not be properly oriented in the pathology department to provide optimal pathologic assessment is an indication for surgery.

Question 5. What should be the pathology reporting standards for malignant colorectal polyps?

Recommendation: We recommend that the pathology report adhere to the recommendation of the College of American Pathologists structured template and that the report contain the histologic type, grade of differentiation, tumor extension/invasion, stalk and mucosal margin status, as well as the presence or absence of lymphovascular invasion. We suggest other aspects, such as specimen integrity, polyp size, polyp morphology, and tumor budding be included.

Weak recommendation; low-quality evidence

Discussion

An organized, consistent system of reporting histopathology findings is essential for improving the quality of post-polypectomy decision-making. Multiple reporting techniques have been proposed, including the adoption of structured checklists (ie, synoptic reporting)^{78,79} as a standardized practice to reduce the chance of omissions and minimize misinterpretations and will further streamline reporting across hospitals and practice groups. The College of American Pathologists provides up-to-date templates for reporting of malignant lesions.⁸⁰ The report should list the location of the tumor site and the endoscopist should include this information with the surgical requisition and in the endoscopic report. The

pathologist should report the specimen integrity, which allows accurate evaluation of the margins. The pathologist should also include the polyp size and polyp morphology (pedunculated or sessile). On microscopic evaluation, the histologic subtype should be reported as classified by the World Health Organization Classification of Colorectal Carcinoma. Additionally, grade should be reported utilizing the 4-tiered grading system, including well-differentiated, moderately differentiated, poorly differentiated, and undifferentiated, with the worst area appreciated driving this categorization. The size of the invasive component should be reported along with the greatest extent of the tumor. The level of invasion of submucosa, measured by an optical micrometer, should be assessed and reported, particularly for nonpedunculated polyps. For the deep margins, the distance of the invasive carcinoma from the deepest resection margin should be reported (typically in millimeters). Another important finding to report is the presence or absence of lymphovascular invasion. Occasionally, the artifact secondary to specimen processing or thermoelectric artifact may inhibit determination of lymphovascular invasion. Tumor budding should be reported as well, if observed. Typically, tumor budding is calculated in a hotspot with the highest density of tumor budding.

Question 6. Who should be involved in the multidisciplinary management of patients with malignant polyps?

Recommendation: We suggest establishing methods of communication among the gastroenterologist, pathologist, oncologist, surgeon, and the patient for the management of patients with malignant polyps.

Weak recommendation; Low-quality evidence

Discussion

Managing patients with malignant colonic polyps should involve a multidisciplinary approach for optimal outcomes. Interdisciplinary cooperation among the gastroenterologist, pathologist, oncologist, and surgeon is highly desirable, as there are multiple steps required in diagnosing, assessing, and providing definitive treatment. The multidisciplinary approach can involve the patient's primary care provider and other medical specialists (eg, a cardiologist), particularly in cases where the patient's comorbid disease might be significant and life expectancy is decreased. The endoscopist should be prepared to coordinate patient care and decision-making. The main question to address is whether the individual should undergo adjuvant surgical resection, and the answer requires weighing the risk of residual cancer or risk of recurrence after endoscopic resection vs the risk of surgical resection. The decision is individualized based on patient factors (eg, age,

comorbidity, and patient preferences) and polyp features (eg, size and histology). The physician's role is to provide an educated assessment of the risk of residual or metastatic disease and the risk of surgery. In some cases, the decision is straightforward. For example, in a healthy patient with any unfavorable histologic criterion, surgical resection is generally advisable. In a poor surgical candidate whose tumor has no unfavorable features, surgery clearly should be avoided. However, when treating an 85-year-old patient with several comorbidities, a decision to forgo surgery may be appropriate even when an unfavorable histologic feature is present. Similarly, a young healthy person with a very low risk for surgical resection might choose surgery to eliminate the risk of cancer even when all histologic features are favorable. In a 55-year-old otherwise healthy individual with a sessile, large malignant polyp with deep submucosal invasion or other unfavorable histologic features, surgery would be appropriate. Patient values are important in cases where the risk of residual cancer and the risk of surgical mortality are similar. In these latter cases, shared decision-making is emphasized. The overall mortality after colon cancer surgery is 1%–8% and correlates with patient age and comorbidities.^{81,82} The goal of management of malignant polyps is to reduce over- and underuse of surgery, while minimizing the chances of recurrent or metastatic cancer.

In summary, the optimal approach to management of malignant polyps begins with a thorough and knowledgeable endoscopic assessment designed to identify features of deep submucosal invasion. In nonpedunculated lesions with features of deep submucosal invasion, endoscopic biopsy is followed by surgical resection. In cases without features of deep submucosal invasion, en bloc resection and proper specimen handling should be considered (if feasible) for lesions with a high risk of superficial submucosal invasion. When pathology reports cancer in a lesion that was completely resected endoscopically, the decision to recommend adjuvant surgery is based on polyp shape, whether there was en bloc resection and adequate histologic assessment, the presence or absence of unfavorable histologic features, the patient's risk for surgical mortality and morbidity, and patient preferences.

REFERENCES

- Vogelstein B, Fearon ER, Hamilton SR, et al. Genetic alterations during colorectal-tumor development. *N Engl J Med* 1988;319:525-32.
- Amin MB, Greene FL, Edge SB, et al. The Eighth Edition AJCC Cancer Staging Manual: continuing to build a bridge from a population-based to a more "personalized" approach to cancer staging. *CA Cancer J Clin* 2017;67:93-9.
- Hackelsberger A, Fruhmorgen P, Weiler H, et al. Endoscopic polypectomy and management of colorectal adenomas with invasive carcinoma. *Endoscopy* 1995;27:153-8.
- Hermanek P, Fruhmorgen P, Guggenmoos-Holzmann I, et al. The malignant potential of colorectal polyps—a new statistical approach. *Endoscopy* 1983;15:16-20.
- Netzer P, Forster C, Biral R, et al. Risk factor assessment of endoscopically removed malignant colorectal polyps. *Gut* 1998;43:669-74.
- Peery AF, Shaheen NJ, Cools KS, et al. Morbidity and mortality after surgery for nonmalignant colorectal polyps. *Gastrointest Endosc* 2018;87:243-50.e2.
- Peery AF, Cools KS, Strassle PD, et al. Increasing rates of surgery for patients with nonmalignant colorectal polyps in the United States. *Gastroenterology* 2018;154:1352-60.e3.
- Guyatt GH, Oxman AD, Vist GE, et al. GRADE: an emerging consensus on rating quality of evidence and strength of recommendations. *BMJ* 2008;336:924-6.
- Benson AB 3rd, Venook AP, Cederquist L, et al. Colon Cancer, Version 1.2017, NCCN Clinical Practice Guidelines in Oncology. *J Natl Compr Canc Netw* 2017;15:370-98.
- Schlemper RJ, Riddell RH, Kato Y, et al. The Vienna classification of gastrointestinal epithelial neoplasia. *2000*;47:251-5.
- Choi JY, Jung SA, Shim KN, et al. Meta-analysis of predictive clinicopathologic factors for lymph node metastasis in patients with early colorectal carcinoma. *J Korean Med Sci* 2015;30:398-406.
- Hewett DG, Kaltenbach T, Sano Y, et al. Validation of a simple classification system for endoscopic diagnosis of small colorectal polyps using narrow-band imaging. *Gastroenterology* 2012;143:599-607.e1.
- Hayashi N, Tanaka S, Hewett DG, et al. Endoscopic prediction of deep submucosal invasive carcinoma: validation of the narrow-band imaging international colorectal endoscopic (NICE) classification. *Gastrointest Endosc* 2013;78:625-32.
- Rastogi A, Keighley J, Singh V, et al. High accuracy of narrow band imaging without magnification for the real-time characterization of polyp histology and its comparison with high-definition white light colonoscopy: a prospective study. *Am J Gastroenterol* 2009;104:2422-30.
- Zhou QJ, Yang JM, Fei BY, et al. Narrow-band imaging endoscopy with and without magnification in diagnosis of colorectal neoplasia. *World J Gastroenterol* 2011;17:666-70.
- Sumimoto K, Tanaka S, Shigita K, et al. Clinical impact and characteristics of the narrow-band imaging magnifying endoscopic classification of colorectal tumors proposed by the Japan NBI Expert Team. *Gastrointest Endosc* 2017;85:816-21.
- Kudo S. Endoscopic mucosal resection of flat and depressed types of early colorectal cancer. *Endoscopy* 1993;25:455-61.
- Kudo S, Tamura S, Nakajima T, et al. Diagnosis of colorectal tumorous lesions by magnifying endoscopy. *Gastrointest Endosc* 1996;44:8-14.
- Kiesslich R, von Bergh M, Hahn M, et al. Chromoendoscopy with indigocarmine improves the detection of adenomatous and nonadenomatous lesions in the colon. *Endoscopy* 2001;33:1001-6.
- Tischendorf JJ, Wasmuth HE, Koch A, et al. Value of magnifying chromoendoscopy and narrow band imaging (NBI) in classifying colorectal polyps: a prospective controlled study. *Endoscopy* 2007;39:1092-6.
- Liu HH, Kudo SE, Juch JP. Pit pattern analysis by magnifying chromoendoscopy for the diagnosis of colorectal polyps. *J Formos Med Assoc* 2003;102:178-82.
- Su MY, Hsu CM, Ho YP, et al. Comparative study of conventional colonoscopy, chromoendoscopy, and narrow-band imaging systems in differential diagnosis of neoplastic and nonneoplastic colonic polyps. *Am J Gastroenterol* 2006;101:2711-6.
- Li M, Ali SM, Umm-a-Omarah Gilani S, et al. Kudo's pit pattern classification for colorectal neoplasms: a meta-analysis. *World J Gastroenterol* 2014;20:12649-56.
- Kanao H, Tanaka S, Oka S, et al. Narrow-band imaging magnification predicts the histology and invasion depth of colorectal tumors. *Gastrointest Endosc* 2009;69:631-6.
- Sano Y, Ikematsu H, Fu KI, et al. Meshed capillary vessels by use of narrow-band imaging for differential diagnosis of small colorectal polyps. *Gastrointest Endosc* 2009;69:278-83.
- Wada Y, Kudo SE, Kashida H, et al. Diagnosis of colorectal lesions with the magnifying narrow-band imaging system. *Gastrointest Endosc* 2009;70:522-31.

27. Nikami T, Saito S, Tajiri H, et al. The evaluation of histological atypia and depth of invasion of colorectal lesions using magnified endoscopy with narrow-band imaging. *Gastroenterol Endosc* 2009;5:10-9.
28. Bisschops R, Hassan C, Bhandari P, et al. BASIC (BLI Adenoma Serrated International Classification) classification for colorectal polyp characterization with blue light imaging. *Endoscopy* 2018;50:211-20.
29. Ikematsu H, Matsuda T, Emura F, et al. Efficacy of capillary pattern type IIIA/IIIB by magnifying narrow band imaging for estimating depth of invasion of early colorectal neoplasms. *BMC Gastroenterol* 2010;10:33.
30. The Paris endoscopic classification of superficial neoplastic lesions: esophagus, stomach, and colon: November 30 to December 1, 2002. *Gastrointest Endosc* 2003;58:S3-43.
31. van Doorn SC, Hazewinkel Y, East JE, et al. Polyp morphology: an inter-observer evaluation for the Paris classification among international experts. *Am J Gastroenterol* 2015;110:180-7.
32. Okamoto T, Tanaka S, Haruma K, et al. [Clinicopathologic evaluation on colorectal laterally spreading tumor (LST)]. *Nihon Shokakibyō Gakkai Zasshi* 1996;93:83-9.
33. Facciorusso A, Antonino M, Di Maso M, et al. Non-polypoid colorectal neoplasms: classification, therapy and follow-up. *World J Gastroenterol* 2015;21:5149-57.
34. Uraoka T, Saito Y, Matsuda T, et al. Endoscopic indications for endoscopic mucosal resection of laterally spreading tumours in the colorectum. *Gut* 2006;55:1592-7.
35. Kudo S, Lambert R, Allen JI, et al. Nonpolypoid neoplastic lesions of the colorectal mucosa. *Gastrointest Endosc* 2008;68:S3-47.
36. Uno Y, Munakata A. The non-lifting sign of invasive colon cancer. *Gastrointest Endosc* 1994;40:485-9.
37. Ishiguro A, Uno Y, Ishiguro Y, et al. Correlation of lifting versus non-lifting and microscopic depth of invasion in early colorectal cancer. *Gastrointest Endosc* 1999;50:329-33.
38. Kobayashi N, Saito Y, Sano Y, et al. Determining the treatment strategy for colorectal neoplastic lesions: endoscopic assessment or the non-lifting sign for diagnosing invasion depth? *Endoscopy* 2007;39:701-5.
39. Kikuchi R, Takano M, Takagi K, et al. Management of early invasive colorectal cancer. Risk of recurrence and clinical guidelines. *Dis Colon Rectum* 1995;38:1286-95.
40. Haggitt RC, Glotzbach RE, Soffer EE, et al. Prognostic factors in colorectal carcinomas arising in adenomas: implications for lesions removed by endoscopic polypectomy. *Gastroenterology* 1985;89:328-36.
41. Moss A, Bourke MJ, Williams SJ, et al. Endoscopic mucosal resection outcomes and prediction of submucosal cancer from advanced colonic mucosal neoplasia. *Gastroenterology* 2011;140:1909-18.
42. Burgess NG, Hourigan LF, Zanati SA, et al. Risk stratification for covert invasive cancer among patients referred for colonic endoscopic mucosal resection: a large multicenter cohort. *Gastroenterology* 2017;153:732-42.e1.
43. Kim HG, Thosani N, Banerjee S, et al. Effect of prior biopsy sampling, tattoo placement, and snare sampling on endoscopic resection of large nonpedunculated colorectal lesions. *Gastrointest Endosc* 2015;81:204-13.
44. Matsuda T, Fukuzawa M, Uraoka T, et al. Risk of lymph node metastasis in patients with pedunculated type early invasive colorectal cancer: a retrospective multicenter study. *Cancer Sci* 2011;102:1693-7.
45. Rembacken BJ, Fujii T, Cairns A, et al. Flat and depressed colonic neoplasms: a prospective study of 1000 colonoscopies in the UK. *Lancet* 2000;355:1211-4.
46. Suzuki N, Talbot IC, Saunders BP. The prevalence of small, flat colorectal cancers in a Western population. *Colorectal Dis* 2004;6:15-20.
47. Diebold MD, Samalin E, Merle C, et al. Colonic flat neoplasia: frequency and concordance between endoscopic appearance and histological diagnosis in a French prospective series. *Am J Gastroenterol* 2004;99:1795-800.
48. dos Santos CE, Malaman D, Monkemuller K, et al. Prevalence of non-polypoid colorectal neoplasms in southern Brazil. *Dig Endosc* 2015;27:361-7.
49. Miyachi H, Kudo SE, Ichimasa K, et al. Management of T1 colorectal cancers after endoscopic treatment based on the risk stratification of lymph node metastasis. *J Gastroenterol Hepatol* 2016;31:1126-32.
50. Nusko G, Mansmann U, Partzsch U, et al. Invasive carcinoma in colorectal adenomas: multivariate analysis of patient and adenoma characteristics. *Endoscopy* 1997;29:626-31.
51. Consolo P, Luigiano C, Strangio G, et al. Efficacy, risk factors and complications of endoscopic polypectomy: ten year experience at a single center. *World J Gastroenterol* 2008;14:2364-9.
52. Hurlstone DP, Sanders DS, Cross SS, et al. Colonoscopic resection of lateral spreading tumours: a prospective analysis of endoscopic mucosal resection. *Gut* 2004;53:1334-9.
53. Oka S, Tanaka S, Kanao H, et al. Therapeutic strategy for colorectal laterally spreading tumor. *Dig Endosc* 2009;21(Suppl 1):S43-6.
54. Seitz U, Bohnacker S, Seewald S, et al. Is endoscopic polypectomy an adequate therapy for malignant colorectal adenomas? Presentation of 114 patients and review of the literature. *Dis Colon Rectum* 2004;47:1789-96; discussion 1796-1797.
55. Geraghty JM, Williams CB, Talbot IC. Malignant colorectal polyps: venous invasion and successful treatment by endoscopic polypectomy. *Gut* 1991;32:774-8.
56. Mojtahed A, Shimoda T. Proper pathologic preparation and assessment of endoscopic mucosal resection and endoscopic submucosal dissection specimens. *Techn Gastrointest Endosc* 2011;13:95-9.
57. Butte JM, Tang P, Gonen M, et al. Rate of residual disease after complete endoscopic resection of malignant colonic polyp. *Dis Colon Rectum* 2012;55:122-7.
58. Aarons CB, Shanmugan S, Bleier JI. Management of malignant colon polyps: current status and controversies. *World J Gastroenterol* 2014;20:16178-83.
59. Bosch SL, Teerenstra S, de Wilt JH, et al. Predicting lymph node metastasis in pT1 colorectal cancer: a systematic review of risk factors providing rationale for therapy decisions. *Endoscopy* 2013;45:827-34.
60. Mou S, Soetikno R, Shimoda T, et al. Pathologic predictive factors for lymph node metastasis in submucosal invasive (T1) colorectal cancer: a systematic review and meta-analysis. *Surg Endosc* 2013;27:2692-703.
61. Kitajima K, Fujimori T, Fujii S, et al. Correlations between lymph node metastasis and depth of submucosal invasion in submucosal invasive colorectal carcinoma: a Japanese collaborative study. *J Gastroenterol* 2004;39:534-43.
62. Hassan C, Zullo A, Risio M, et al. Histologic risk factors and clinical outcome in colorectal malignant polyp: a pooled-data analysis. *Dis Colon Rectum* 2005;48:1588-96.
63. Beaton C, Twine CP, Williams GL, et al. Systematic review and meta-analysis of histopathological factors influencing the risk of lymph node metastasis in early colorectal cancer. *Colorectal Dis* 2013;15:788-97.
64. Cooper HS. Surgical pathology of endoscopically removed malignant polyps of the colon and rectum. *Am J Surg Pathol* 1983;7:613-23.
65. Nivatvongs S, Rojanasakul A, Reiman HM, et al. The risk of lymph node metastasis in colorectal polyps with invasive adenocarcinoma. *Dis Colon Rectum* 1991;34:323-8.
66. Morson BC, Whiteway JE, Jones EA, et al. Histopathology and prognosis of malignant colorectal polyps treated by endoscopic polypectomy. *Gut* 1984;25:437-44.
67. Cooper HS, Deppisch LM, Gourley WK, et al. Endoscopically removed malignant colorectal polyps: clinicopathologic correlations. *Gastroenterology* 1995;108:1657-65.
68. Netzer P, Binek J, Hammer B, et al. Significance of histologic criteria for the management of patients with malignant colorectal polyps and polypectomy. *Scand J Gastroenterol* 1997;32:910-6.
69. Cioaltea A, Gheonea DI, Saftoiu A, et al. Current strategies for malignant pedunculated colorectal polyps. *World J Gastrointest Oncol* 2018;10:465-75.
70. Bujanda L, Cosme A, Gil I, et al. Malignant colorectal polyps. *World J Gastroenterol* 2010;16:3103-11.

71. Quirke P, Riso M, Lambert R, et al. Quality assurance in pathology in colorectal cancer screening and diagnosis-European recommendations. *Virchows Arch* 2011;458:1-19.
72. Boenicke L, Fein M, Sailer M, et al. The concurrence of histologically positive resection margins and sessile morphology is an important risk factor for lymph node metastasis after complete endoscopic removal of malignant colorectal polyps. *Int J Colorectal Dis* 2010;25:433-8.
73. Harris EI, Lewin DN, Wang HL, et al. Lymphovascular invasion in colorectal cancer: an interobserver variability study. *Am J Surg Pathol* 2008;32:1816-21.
74. Coverlizza S, Riso M, Ferrari A, et al. Colorectal adenomas containing invasive carcinoma. Pathologic assessment of lymph node metastatic potential. *Cancer* 1989;64:1937-47.
75. Ogawa T, Yoshida T, Tsuruta T, et al. Tumor budding is predictive of lymphatic involvement and lymph node metastases in submucosal invasive colorectal adenocarcinomas and in non-polypoid compared with polypoid growths. *Scand J Gastroenterol* 2009;44:605-14.
76. Zhang Q, Wang L, Huang D, et al. Pathological risk factors for lymph node metastasis in patients with submucosal invasive colorectal carcinoma. *Cancer Manag Res* 2019;11:1107-14.
77. Lugli A, Kirsch R, Ajioka Y, et al. Recommendations for reporting tumor budding in colorectal cancer based on the International Tumor Budding Consensus Conference (ITBCC) 2016. *Mod Pathol* 2017;30:1299-311.
78. Idowu MO, Bekeris LG, Raab S, et al. Adequacy of surgical pathology reporting of cancer: a College of American Pathologists Q-Probes study of 86 institutions. *Arch Pathol Lab Med* 2010;134:969-74.
79. Srigley JR, McGowan T, Maclean A, et al. Standardized synoptic cancer pathology reporting: a population-based approach. *J Surg Oncol* 2009;99:517-24.
80. Pathology Working Group Report. National Colorectal Cancer Screening Network. Classification of Benign Polyps, . https://www.cap-acp.org/cmsUploads/CAP/File/Classification_of_Benign_Polyps_-_Pathology_Working_Group_National_Colorectal_Cancer_Screening_Network.pdf. Published June 2011. Accessed June 15, 2020.
81. Iversen LH, Nielsen H, Pedersen L, et al. Seasonal variation in short-term mortality after surgery for colorectal cancer? *Colorectal Dis* 2010;12:e31-6.
82. Paulson EC, Mitra N, Sonnad S, et al. National Cancer Institute designation predicts improved outcomes in colorectal cancer surgery. *Ann Surg* 2008;248:675-86.

resection; GRADE, Grading of Recommendations Assessment, Development and Evaluation; JNET, Japanese Narrow Band Imaging Expert Team; LNM, lymph node metastasis; LST-G, laterally spreading tumor, granular type; LST-NG, laterally spreading tumor, nongranular type; NBI, narrow band imaging; NICE, Narrow Band Imaging International Colorectal Endoscopic; OR, odds ratio; RR, relative risk; USMSTF, US Multi-Society Task Force on Colorectal Cancer.

Conflicts of interest: The authors disclose no conflicts of interest relative to the current work since 2016. Industry relationships for authors (consulting, research, reimbursement) without conflict of interest relevant to the current work since 2016: D. K. Rex (Olympus, Boston Scientific, Covidien, Lumendi, Salix, Aries, Cook Medical, ERBE, Bausch Health Inc, Novo Nordisk, Endochoice, Braintree Laboratories, Norgine, Endokey, EndoAid, Medivators, Satisfai Health); Sapna Syngal (Chirhoclin, Cook, Myriad Genetics, Inc, DC Health, Inc); D. Lieberman (Covidien, Freenome Holdings, Inc, Ironwood, Check-Cap, CEGX); D. Robertson (Covidien, Freenome Holdings, Inc, Amadix); T. Kaltenbach (Aries Pharmaceuticals, Micro-Tech Endoscopy, Olympus, Boston Scientific, Medtronic); A. Shaukat (Iterative Scopes, Freenome Holdings Inc); S. Gupta (Freenome Holdings, Inc, Guardant Health, Inc, Mallinckrodt Pharmaceuticals); C. Burke (Salix Pharmaceuticals, Ferring Pharmaceuticals, Aries Pharmaceuticals, Pfizer, Cancer Prevention Pharmaceuticals, Janssen Pharmaceuticals, SLA Pharma AG; Freenome Holdings, Inc). The remaining authors disclose no conflicts.

Current affiliations: Minneapolis Veterans Affairs Health Care System, Minneapolis, Minnesota (1), University of Minnesota, Minneapolis, Minnesota (2), Veterans Affairs San Francisco, University of California-San Francisco, San Francisco, California (3), Veterans Affairs Puget Sound Health Care System, Seattle, Washington (4), University of Washington School of Medicine, Seattle, Washington (5), Veterans Affairs Medical Center, White River Junction, Vermont (6), Geisel School of Medicine at Dartmouth, Hanover, New Hampshire (7), University of Connecticut, Farmington, Connecticut (8), Cleveland Clinic, Cleveland, Ohio (9), San Diego Veterans Affairs Medical Center, San Diego, California (10), University of California-San Diego, San Diego, California (11), Portland Veterans Affairs Medical Center, Portland, Oregon (12), Oregon Health and Science University, Portland, Oregon (13), Brigham and Women's Hospital, Boston, Massachusetts (14), Dana-Farber Cancer Institute, Boston, Massachusetts (15), Harvard Medical School, Boston, Massachusetts (16), Indiana University School of Medicine, Indianapolis, Indiana (17).

Reprint requests: Aasma Shaukat, MD, MPH, One-Veterans drive, 111-D, Minneapolis, Minnesota 55417. E-mail: Shaukat@umn.edu.

Abbreviations: AJCC, American Joint Committee on Cancer; CI, confidence interval; CRC, colorectal cancer; EMR, endoscopic mucosal

APPENDIX 1.**Database: All Ovid MEDLINE(R) <1946 to Present>****Search Strategy:**

- 1 colonic polyps/ (7377)
- 2 endoscop:.mp. (204331)
- 3 1 and 2 (2234)
- 4 (malignan: or (musocal adj resect:) or (submucosal adj dissect:)).ti,ab. (477312)
- 5 (t1 or tumor: or tumour:).ti,ab. (1448687)
- 6 (paris or kudos).ti,ab. (12395)
- 7 4 or 5 or 6 (1697658)
- 8 3 and 7 (545)
- 9 limit 8 to (english language and yr="1980 -Current" and "all adult (19 plus years)") (300)
- 10 colonic polyps/ (7377)
- 11 endoscop:.mp. (204331)
- 12 10 and 11 (2234)
- 13 limit 12 to (english language and "all adult (19 plus years)") (1273)
- 14 limit 13 to yr="1980 -Current" (1273)
- 15 endoscopes/ or endoscopy/ (50630)
- 16 colonoscopy/ or duodenoscopy/ (25683)
- 17 14 and (15 or 16) (968)
- 18 colonic polyps/pa (3064)
- 19 assess:.mp. (2514976)

20 18 and 19 (540)

21 limit 20 to (english language and yr="1980 -Current" and "all adult (19 plus years)") (359)

22 21 not 17 (203)

23 multidisciplin:.mp. (60330)

24 patient care team/ (58291)

25 interdisciplinary communication/ (14073)

26 exp "Health Services Needs and Demand"/ (54600)

27 23 or 24 or 25 or 26 (172588)

28 10 and 27 (30)

29 limit 28 to (english language and yr="1980 -Current" (22)

Database: All Ovid MEDLINE(R) <1946 to Present>**Search Strategy:**

1 colonic polyps/ (7377)

2 endoscop:.mp. (204331)

3 1 and 2 (2234)

4 (malignan: or (musocal adj resect:) or (submucosal adj dissect:)).ti,ab. (477312)

5 (t1 or tumor: or tumour:).ti,ab. (1448687)

6 (paris or kudos).ti,ab. (12395)

7 4 or 5 or 6 (1697658)

8 3 and 7 (545)

9 limit 8 to (english language and yr="1980 -Current" and "all adult (19 plus years)") (300)